

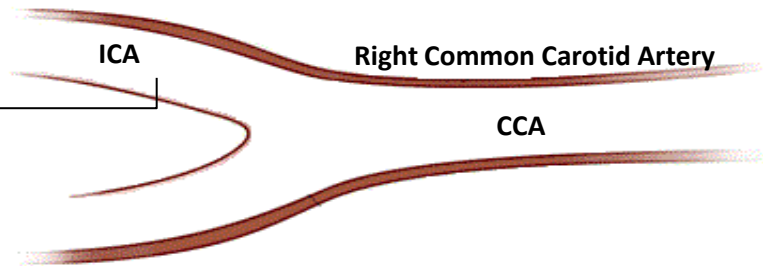


Carotid Duplex Report

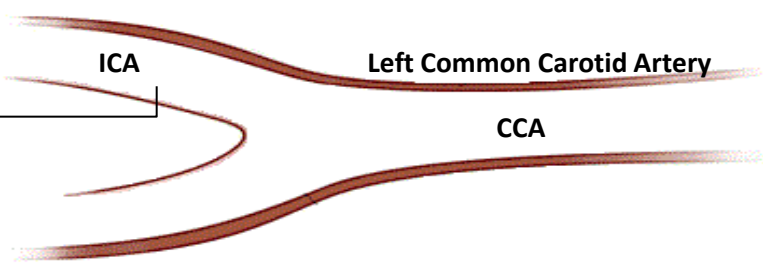
Patient Name: CESTERO, GRETCHEN
DOB: 28-Sep-55

Physician: GALAN
Exam Date: 9-Apr-21

Right	ICA	CCA
*PSV:	78	71
*EDV:	14	16
RICA STENOSIS:	< 20%	



Left	ICA	CCA
*PSV:	72	68
*EDV:	13	16
LICA STENOSIS:	< 20%	



Left Vertebral Artery
Velocity: 52
Direction: Antegrade

Right Vertebral Artery
Velocity: 55
Direction: Antegrade

Vertebral Artery



COMMENT: Dynamic ultrasound scanning of the neck was performed with carotid duplex (Doppler & B-Mode ultrasound) arterial analysis including color flow and spectral analysis; Impression: Normal bilateral carotid duplex ultrasound exam.

Physicians Signature: _____



